

ARTICULAR GOUT IN A VARIED LORIKEET (CASE 711.1)

CASE HISTORY

Varied lorikeet, unable to perch. All joints on the right and left feet are inflexible. Many joints of the feet contain white/cream material. Scant radiographic changes in the limbs. Fine needle biopsy taken of the white articular material positive for urate granules. Euthanasia elected.

GROSS PATHOLOGY



Fig 1. Articular gout- note white tophi

External findings: Abundant white, chalky material distends many joints. This white material distended the joints of the carpus, manus, spine, right hip, stifles, tarsi, metatarsi, and interphalangeal joints.

Hydration, Muscle mass, Fat deposits: good

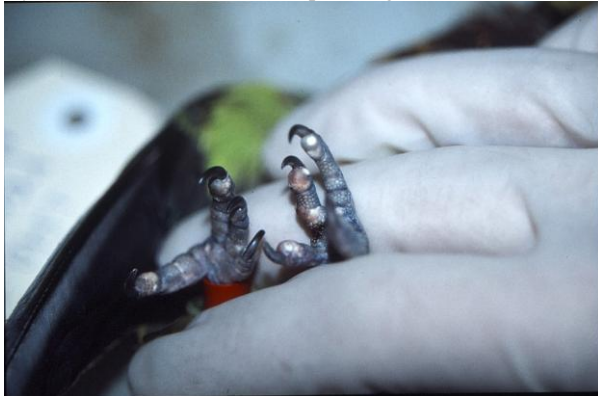

Fig 2. Articular gout- note white tophi

Internal findings: The gastrointestinal tract contains scant ingesta. The kidneys are moderately mottled with pale foci. There are multiple 1 mm white foci along the epicardium at the base of the heart.

CYTOLOGY:

Cytologic examination of the joint aspirate revealed many refractile spicules, which polarised under light microscopy (Fig 3).

HISTOLOGY:

Lesions are not evident within the following tissues: Brain, liver, proventriculus, ventriculus, pancreas, colon, small intestine, skeletal muscle, myocardium, spinal cord

Spleen: The splenic parenchyma contains numerous lymphoid follicles.

Kidney: The renal interstitium contains a small focal lymphoid cell infiltrate.

Testes: Spermatogenesis is not evident within spermatoc cords.

Skeletal muscle: Epaxial: Multiple skeletal myocytes have cytoplasm that has lost its striated pattern and become granular. Some myocytes have globular degeneration of myofibrils and exhibit contraction band formation.

Tarsus: A cross section near the joint demonstrates large aggregates of eosinophilic amorphous material within the periosteal tissues. The eosinophilic material often bears the negative impression of radiating spicules. The material is most often surrounded by mononuclear cells or multinucleate giant cells. Focally, an aggregate is evident directly opposed to the cortical bone. Osteoclasts line the bone surface that is exposed to this material. Along another segment of cortical bone, however, the eosinophilic material is adjacent to a segment of cortex that appears to have produced a layer of cartilage along the periosteal surface. Large quantities of mature fibrous tissue surround the eosinophilic amorphous material. A longitudinal section of the tarsus demonstrates multifocal segmental replacement of the synovial epithelium with a thick layer of the eosinophilic material described above. This material is lined by a layer of macrophages and multinucleate giant cells and then a peripheral layer of dense connective tissue.

Toe: Several large aggregates of eosinophilic material, as described above, are evident within the subcutaneous tissues.

The cortex of the second phalanx is highly irregular. The periosteum contains a small core of bone and cartilage adjacent to one of the eosinophilic aggregates described above. Within a cross section of another toe there are very large aggregates of eosinophilic amorphous material.

MORPHOLOGICAL DIAGNOSIS

Euthanasia

Articular gout

COMMENTS

The bird was euthanased due to severe articular gout. There is no evidence of additional significant underlying disease. The renal tissues appear normal. The pathogenesis of gout is not fully understood but renal and dietary (especially excess dietary protein) are most likely the major factors.




Fig 3. Joint aspirate showing urate crystals under normal (a) and polarized (b) light microscopy.

REFERENCES

GARTRELL, B. D. RAIDAL, S. R. JONES, S. M. Renal disease in captive swift parrots (*Lathamus discolor*): clinical findings and disease management. *Journal of Avian Medicine and Surgery*. 2003. 17(4): 213-223.

KOUTSOS, E. A. SMITH, J. WOODS, L. W. KLASING, K. C. Adult cockatiels (*Nymphicus hollandicus*) metabolically adapt to high protein diets. *Journal of Nutrition*. 2001. 131(7): 2014-2020.

KOLMSTETTER, C. M. RAMSAY, E. C. Effects of feeding on plasma uric acid and urea concentrations in blackfooted penguins (*Spheniscus demersus*). *Journal of Avian Medicine and Surgery*. 2000. 14(3): 177-179.